

Fatal gastrointestinal bleeding from an aortic pseudo-aneurysm in a patient with oesophageal perforation and Salmonella mediastinitis

Mohamed Al-Tashi¹, Miroslav Lojik², Pavel Žáček³, Stanislav Rejchrt¹, Jan Bureš¹

¹2nd Department of Internal Medicine, Charles University in Praha, Faculty of Medicine at Hradec Králové, University Teaching Hospital, Hradec Králové, Czech Republic

²Department of Radiology, Charles University in Praha, Faculty of Medicine at Hradec Králové, University Teaching Hospital, Hradec Králové, Czech Republic

³Department of Cardiac Surgery, Charles University in Praha, Faculty of Medicine at Hradec Králové, University Teaching Hospital, Hradec Králové, Czech Republic

Summary

We report a quite unusual case of fatal bleeding from an aortic pseudo-aneurysm. The probable sequence was swallowing of a foreign body, oesophageal perforation, mediastinitis and aortic pseudo-aneurysm

formation. In our case, the oesophageal stent placement together with antibiotic treatment contributed to healing of mediastinitis but did not prevent fatal bleeding from the aortic pseudo-aneurysm.

KEY WORDS: OESOPHAGEAL PERFORATION, SALMONELLA MEDIASTINITIS, AORTIC PSEUDO-ANEURYSM, FATAL GASTROINTESTINAL BLEEDING

Souhrn

Smrtící gastrointestinální krvácení z pseudoaneuryzmatu aorty u nemocné s perforací jícnu a salmonelovou mediastinitidou.

Kazuistika přináší popis neobvyklého případu smrtícího krvácení z pseudoaneuryzmatu aorty u 82leté nemocné. Pravdě-

podobnou příčinou perforace jícnu bylo spolknuté cizí těleso. Komplikující mediastinitida byla způsobena infekcí Salmonella enteritidis. Zavedený metalický expandibilní jícnový stent spolu s antibiotickou léčbou přispěly ke zhojení mediastinitidy. Jako komplikace mediastinitidy však

vzniklo pseudoaneuryzma aorty. Druhá ataka akutního krvácení z pseudoaneuryzmatu byla fatální.

KLÍČOVÁ SLOVA: PERFORACE JÍČNU, SALMONELOVÁ MEDIASTINITIS, PSEUDOANEURYZMA AORTY, FATÁLNÍ GASTROINTESTINÁLNÍ KRVÁCENÍ

Oesophageal perforation is an unusual pathologic condition. About 75% of cases are iatrogenic, traumatic open wounds are rare. The worst complication of oesophageal perforation is mediastinitis. In our case the oesophageal perforation was traumatic by foreign body swallowing and was complicated by mediastinitis and aortic pseudo-aneurysm formation. We report this case among others because of the atypical microbiological agents of mediastinitis – Salmonella enteritidis without intestinal infection.

a long time from ischaemic heart disease with atrial fibrillation, arterial hypertension and diabetes mellitus. She was presented with dysphagia for solids one month before she was admitted to a hospital elsewhere. She was not aware of swallowing any foreign body, nevertheless this event could not be excluded with certainty. For the same time she suffered from intermittent fever, chills and fatigue. On admission, sepsis was diagnosed and antibiotic treatment with ciprofloxacin and cotrimoxazol was introduced. Because of oropharyngeal dysphagia progression even for liquids, an ENT examination was performed and

revealed paresis of the left vocal cord. Subsequent CT scan found pseudo-aneurysm of the aortic arc and inflammatory infiltration in the mediastinum (with a deviation of the oesophagus to the right and presence of free gas in the mediastinum). The patient was transferred to our hospital afterwards. Upper GI endoscopy revealed a perforation of the proximal oesophagus 22 cm from the incisors (Fig. 1). Thick pus ran out the perforation from the mediastinum into the oesophagus. Surprisingly, Salmonella enteritidis together with Candida albicans were cultured from the pus. As the patient was not fit for surgery, the fistula was

CASE REPORT

An 82-year-old woman suffered for

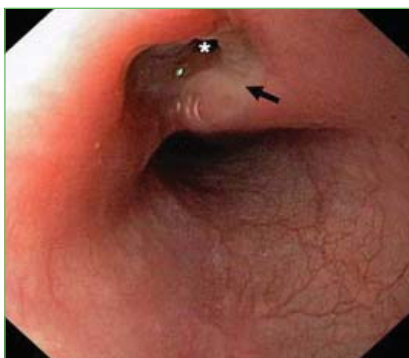

Fig. 1.
Endoscopic view of the perforation of the proximal oesophagus (asterisk) with pus (arrow) running out from the orifice.

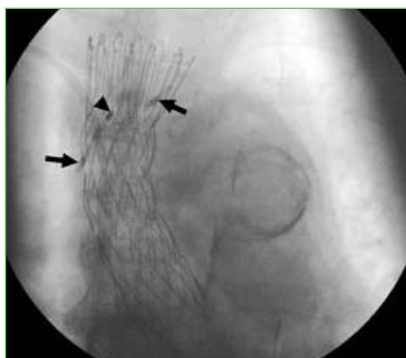


Fig. 2.
Oesophageal stent after deployment. Two hemo-clips (arrows) and radioopaque marking (arrow) on the pursing string at the proximal end of the stent.

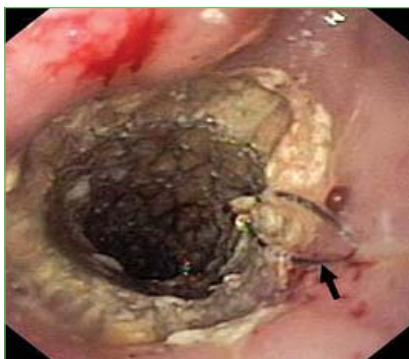

Fig. 3.
An early mucosal in-growth over the upper margin of the stent and through the uncovered part of proximal end. Pursing string marked with an arrow.

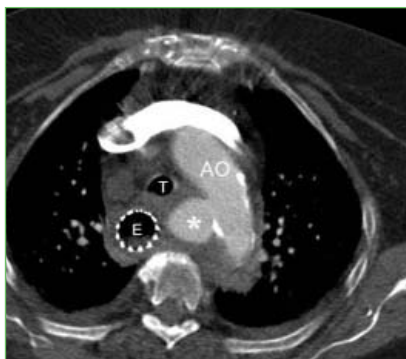

Fig. 4.
Calcified aortic arch (AO) with pseudo/aneurysm (asterisk) and mediastinal haematoma surrounded trachea (T) and the oesophagus (E) with a metallic stent and intraluminal blood clot.

marked with hemo-clips and a covered metallic self-expandable oesophageal stent (FerX-ELLA Boubella E, ELLA-CS, Czech Republic) was introduced to superimpose the oesophageal perforation. This type of stent is made of stainless steel, the flared proximal end is partly uncovered and has pursing string for removal at the proximal end. The patient improved with complex intensive therapy (including meropenem and fluconazole). A control chest X-ray showed the proper position of the oesophageal stent (Fig. 2). An aortic arch pseudo-aneurysm was considered to be an inflammatory aetiology, not suitable for any surgical or endovascular therapy. A control endoscopy two weeks later found an early mucosal in-growth over the upper margin of the stent and through the uncovered part of proximal end (Fig. 3). Pulling out the string

did not release the stent from the oesophagus. Subsequent melaena and drop in haemoglobin level required blood transfusions. Mediastinal haematoma was confirmed on CT scan (Fig. 4) and we turned away from other attempts at stent removal. The bleeding did not continue and the patient's condition stabilised. However, the patient died two weeks later from sudden fatal gastrointestinal bleeding from the aortic pseudo-aneurysm into the oesophagus.

DISCUSSION

We report a quite unusual case of fatal bleeding from an aortic pseudo-aneurysm. The probable sequence was swallowing of a foreign body, oesophageal perforation, mediastinitis and aortic pseudo-aneurysm formation. An aortic pseudo-aneurysm due to an ingested foreign body was

previously published as a case report [1]. The pathological mechanism in such a case may involve oesophageal perforation and direct communication of oesophagus and aorta usually at the level of the aortic arch or more usually following oesophageal perforation, the subsequent mediastinal abscess leads to necrosis of the aortic wall [2]. Salmonella is quite a rare cause of mediastinal infection but it may cause an aorta dissection [3]. Our patient has no history of intestinal infection, so the source of the Salmonella infection remains unclear in this particular case. Placement of a covered, removable metallic or plastic endoprosthesis is a therapeutic option of oesophageal perforation in those patients who are not fit for major surgery [4,5]. In our case, the stent placement together with antibiotic treatment contributed to healing of mediastinitis and improved the overall patient's status but did not prevent fatal bleeding from the aortic pseudo-aneurysm.

Acknowledgement

The study was supported by the research project MZO 00179906 from the Ministry of Health, Czech Republic.

Literature

- Schumacher KJ, Weaver DL, Knight MR, Presberg HJ. Aortic pseudoaneurysm due to ingested foreign body. *South Med J* 1986; 79(2): 246–248.
- Hunt I, Hartley S, Alwahab Y, Birkill GJ. Aorto-oesophageal perforation following ingestion of razor blades with massive haemothorax. *Eur J Cardiothorac Surg* 2007; 31(5): 946–948.
- Fernández-Ayala M, Nan D, Gutierrez JA, Farinas MC. Postoperative mediastinitis due to Salmonella. *Scand J Infect Dis* 2003; 35(1): 67–68.

4. Fischer A, Thomusch O, Benz S et al. Nonoperative treatment of 15 benign esophageal perforations with self-expandable covered metal stents. *Ann Thorac Surg* 2006; 81(2): 467–472.

5. Radecke K, Lang H, Frilling A et al. Successful sealing of benign esophageal leaks after temporary placement of a self-expanding plastic stent without fluoroscopic guidance. *Z Gastroenterol* 2006; 44(10): 1031–1038.

Correspondence to/

Adresa pro korespondenci:

Mohamed M. Al-Tashi, MD

2nd Department of Internal Medicine

Charles University Teaching Hospital

Sokolská 581

500 05 Hradec Králové

Czech Republic

e-mail: altashi@seznam.cz