

Inverted Meckel's diverticulum as a rare cause of severe gastrointestinal bleeding in an elderly patient

Case report of a 67-year-old woman and review of the literature

Jolana Bártová¹, Marcela Kopáčová¹, Ladislav Vykouřil², Zdeněk Vacek³, Věra Tyčová⁴, Rudolf Repák¹, Lukáš Maršík², Tomáš Douda¹, Stanislav Rejchrt¹, Jan Bureš¹

¹2nd Department of Internal Medicine, Charles University in Praha, Faculty of Medicine at Hradec Králové, University Teaching Hospital, Hradec Králové, Czech Republic

²Department of Surgery, Charles University in Praha, Faculty of Medicine at Hradec Králové, University Teaching Hospital, Hradec Králové, Czech Republic

³Department of Radiology, Charles University in Praha, Faculty of Medicine at Hradec Králové, University Teaching Hospital, Hradec Králové, Czech Republic

⁴The Fingerland Department of Pathology, Charles University in Praha, Faculty of Medicine at Hradec Králové, University Teaching Hospital, Hradec Králové, Czech Republic

Summary

We report an unusual case of severe bleeding from inverted Meckel's diverticulum in a 67-year-old woman. Her disease was presented with painless acute gastrointestinal bleeding. Enteroclysis revealed a large pedunculated ileal polyp 80 cm

proximal to the ileo-caecal valve. Intra-operative enteroscopy was carried out as the next step and an inverted Meckel's diverticulum was found with three ulcers. The diverticulum was resected surgically. The postoperative course was uneventful and

the patient was released from hospital ten days later.

KEY WORDS: INVERTED MECKEL'S DIVERTICULUM, ACUTE BLEEDING, INTRA-OPERATIVE ENTEROSCOPY

Souhrn

Reverzní Meckelův divertikl jako neobvyklý zdroj závažného gastrointestinálního krvácení u starší pacientky. Kazuistika 67leté ženy a přehled literatury

V kazuistice je popsán neobvyklý případ závažného krvácení z reverzního Mecke-

lova divertiklu u 67leté ženy. Onemocnění se projevilo bezbolestným akutním gastrointestinálním krvácením. Na enteroklyze byl v ileu, 80 cm před ileocekální chlopní, zjištěn velký pendující polyp. Při intraoperační enteroskopii byl zjištěn

reverzní Meckelův divertikl se třemi ulceracemi. Divertikl byl resekován chirurgicky. Pooperační průběh byl bez komplikací.

KLÍČOVÁ SLOVA: REVERZNÍ MECKELŮV DIVERTIKL, AKUTNÍ KRVÁCENÍ, INTRAOPERAČNÍ ENTEROSKOPIE

Meckel's diverticulum is the most common congenital anomaly of the gastrointestinal tract (1–3% of the population in autopsy studies, twice as more frequently found in males). It derives from incomplete obliteration of the yolk stalk (omphalo-mesenteric duct). Meckel's diverticulum is a true diverticulum with all layers of the intestinal wall present. It arises from the antimesenteric border, located usually 100 cm proximal to the ileo-

caecal valve, has its own mesentery and blood supply from a terminal branch of the superior mesenteric artery. Diverticula that do not contain normal ileal mucosa may harbour ectopic glandular tissue: gastric (~ 50%), duodenal Brunner's glands, pancreatic acinar tissue, colonic mucosa, endometrium, hepatobiliary tissue or their combination. Meckel's diverticulum is usually asymptomatic, only about 2% develop a complication

over the course of their life. 60% of patients having complications are younger than two years, painless bleeding (from peptic ulceration in ectopic gastric mucosa) is the most common. *Helicobacter pylori* may colonise the gastric mucosa of Meckel's diverticulum but it likely plays no role in bleeding diverticula. Other complications of Meckel's diverticulum comprise diverticulitis, iron deficiency anaemia, intestinal obstruction and

perforation (from foreign bodies, diverticulitis, peptic ulceration or blunt abdominal trauma). A longer diverticulum (length > 2 cm) is associated with a higher risk of complications. Bacterial overgrowth, intussusception, volvulus, strangulation, Littre's herniation, phytobezoars, formation of enteroliths and malignant transformation (carcinoid, adenocarcinoma or leiomyosarcoma) are all very unusual [8,9,11,18,21,22,24,25,30,31,38,40].

We report an unusual case of severe gastrointestinal bleeding from inverted Meckel's diverticulum in an elderly patient.

CASE REPORT

A 67-year-old woman was treated for iron deficiency anaemia for the past 5 years. Suddenly her disease was presented with painless severe gastrointestinal bleeding (fresh melaena) elsewhere. Bleeding required 6 units of blood within 24 hours. The source of the bleeding was not identified either by gastroscopy or colonoscopy and the patient was referred to our Department as a case of acute obscure overt bleeding. Enteroclysis revealed a large polyp (8 cm in length) 80 cm proximal to the ileo-caecal valve and nearly obstructing the entire intestinal lumen (Fig. 1). Intra-operative enteroscopy was carried out as the next step and an inverted Meckel's diverticulum was found with three ulcers (one of them with adhering blood clot) (Figs 2, 3). The surgeon decided to resect the diverticulum together with 10 cm of the adjacent ileum. Histology confirmed Meckel's diverticulum. The postoperative course was uneventful and the patient was released from hospital ten days later.

DISCUSSION

We present a remarkable case of inverted Meckel's diverticulum as a quite rare cause of painless severe acute gastrointestinal bleeding. Meckel's diverticulum is the most common

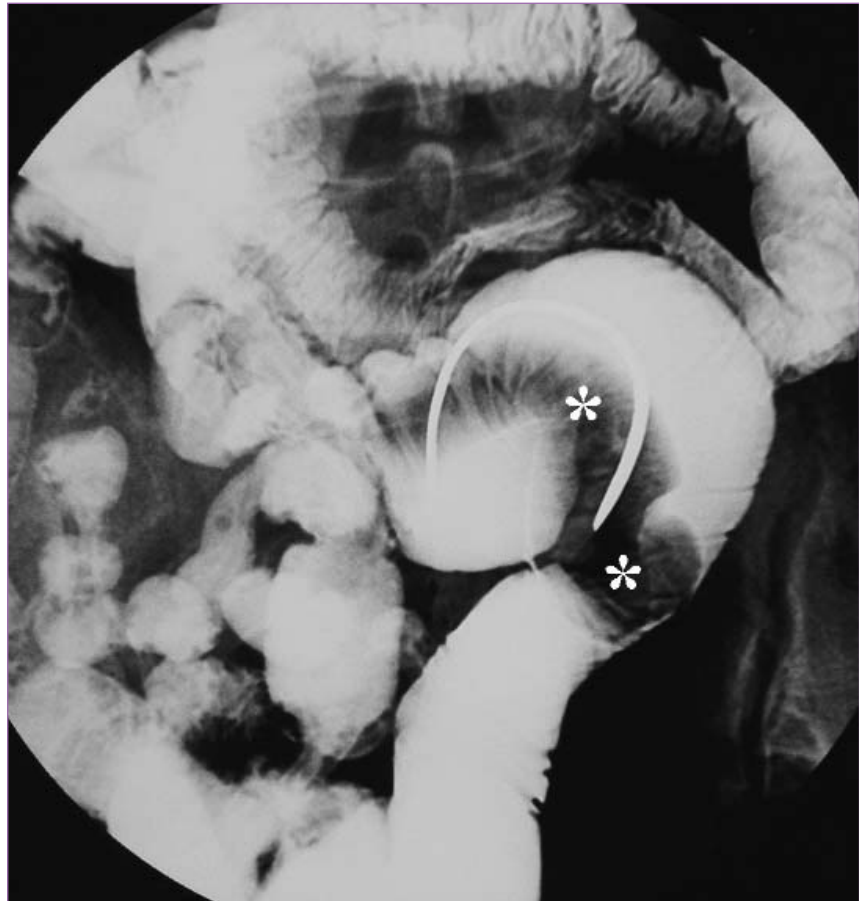


Fig. 1. Enteroclysis. Smoothly margined intraluminal mass in the ileum simulated an intraluminal polyp (asterisks).

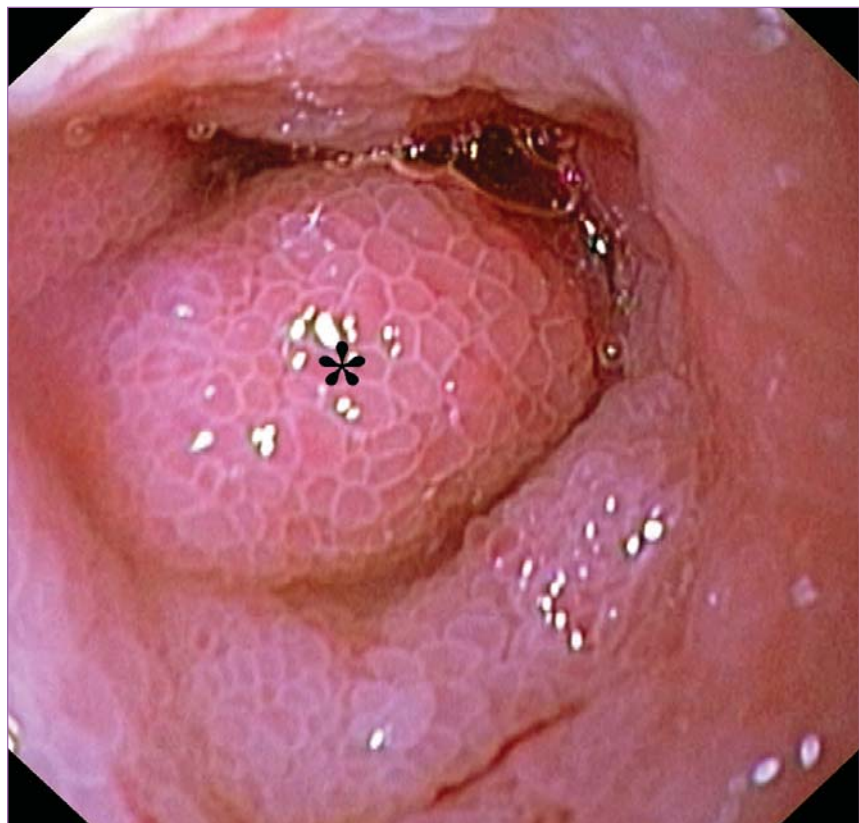


Fig. 2. Intra-operative enteroscopy. Obstruction of the ileum caused by inverted Meckel's diverticulum. Swollen mucosa of the diverticulum is nicely visible (asterisk).

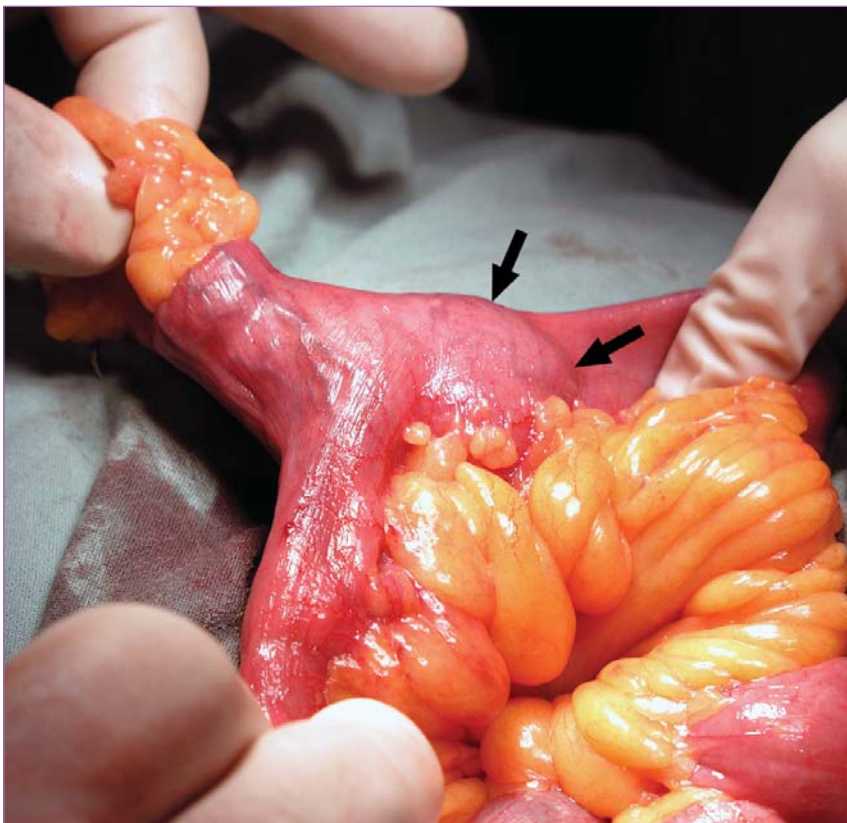


Fig. 3. Surgical field - view of open abdominal cavity. Extraction of the Meckel's diverticulum; large part of it is still inverted (arrows).

congenital anomaly of the gastrointestinal tract but we have found only a few reports of inverted diverticulum [3,6,10,12,14,17,19,29,32,36,39] and only three cases similar to ours [1,20,34]. Other cases presented with iron deficiency anaemia [32], diarrhoea and vomiting [12], strangulated intestinal obstruction [39], intussusception [10,19,36], mimicking tumour [3,6] or Crohn's disease [17]. Once inverted, the diverticulum may serve as the site of intestinal obstruction or lead point for an ileo-ileal or ileo-colic intussusception [25].

More than 2 800 papers were published on Meckel's diverticulum over the past five decades (according to a PubMed search). However, most publications have been either small series or case reports. The largest series was published by Park et al as the Mayo Clinic experience with 1,476 patients (collected from 1950 to 2002) [30]. Only 16% were symptomatic. Among 180 adult patients, bleeding

(69/180; 38%), obstruction (61/180; 34%) and diverticulitis (50/180; 28%) were the most common complications. The authors do not mention any case of inverted Meckel's diverticulum [30].

Soltero and Bill [35] calculated in their retrospective study of 202 patients that lifetime risk of complication from a Meckel's diverticulum is 4% up to the age of 20.2% up to the age of 40 years, and zero in the elderly population. The authors of the Olmsted County (Minnesota) Study stated that the lifetime risk (to 80 years of age) of developing any complication of Meckel's diverticulum was 6.4% [7].

A 99m technetium pertechnetate scintigraphy is a principal investigation, it detects ectopic gastric mucosa in Meckel's diverticulum, pre-treatment with pentagastrin or H_2 -receptor antagonists reduces false negative results. Pentagastrin accelerates Tc uptake and an H_2 -receptor antagonist decreases Tc release by the gastric mucosa

[11]. However, only one half of Meckel's diverticula harbour gastric mucosa. Other diagnostic tools comprise (CT/MRI) enteroclysis [13], intra-operative enteroscopy [23], Doppler ultrasonography [2], angiography [33] and recently wireless capsule endoscopy [16,26,27,37] and double balloon enteroscopy [4,5,15,28].

Abdominal radiographic findings are most often non-specific in these cases unless the patients have intestinal obstruction or intussusception. Enteroclysis shows an elongated, smoothly margined intraluminal mass that parallels the long axis of the intestine and frequently has a bulbous or club-like tip [25]. It may also appear as a pedunculated intraluminal polyp [34]. CT characteristically shows the inverted diverticulum as a central core of fat attenuation surrounded by a collar of soft-tissue attenuation. At sonography, the inverted diverticulum has a target-like appearance with central hyperechogenicity from the core of mesenteric fat or a double target appearance when the entire section of the small intestine containing the inverted diverticulum is visualised [29]. Doppler sonography may reveal anomalous vessels [2]. The differential diagnosis for an elongated tubular filling defect produced by an inverted Meckel's diverticulum on barium images of the small intestine includes elongated pedunculated polyps such as Peutz-Jeghers syndrome [25]. The principal differential diagnosis for an inverted Meckel's diverticulum on CT scans is a lipoma [3,20]. Intestinal lipomas have fat attenuation at CT but they lack the collar of soft-tissue attenuation that is seen in inverted Meckel's diverticulum [25]. When the vitalline artery is seen in the ileal lumen on angiography, inverted Meckel's diverticulum should be considered [33].

In our particular case, inverted Meckel's diverticulum also mimicked elongated pedunculated polyp on

enteroclysis. It was not until intra-operative enteroscopy that the correct diagnosis was determined. Surgical resection in the same anaesthesia provided a final solution.

CONCLUSIONS

Meckel's diverticulum is the most common anomaly of the gastrointestinal tract. However, most of them are asymptomatic lifelong. Clinical symptoms arise from complications of the diverticulum which are very rare in elderly people. Preoperative diagnosis of a complicated Meckel's diverticulum may be challenging because clinical and imaging features overlap with those of other causes of acute abdomen. In case of severe painless acute obscure overt bleeding Meckel's diverticulum should be considered even in elderly patients. Capsule endoscopy, double balloon enteroscopy and ultimately intra-operative enteroscopy may be helpful in timely diagnosis.

Acknowledgements

The study was supported by research project MZO 00179906 from the Ministry of Health.

Literature

1. Andrabi SI, Spence GM, Clements WB. Inversion of Meckel's diverticulum causing gastrointestinal bleeding and small bowel obstruction. *Br J Hosp Med (London)* 2007; 68(8): 442–443.
2. Baldisserotto M, Maffazzoni DR, Dora MD. Sonographic findings of Meckel's diverticulitis in children. *AJR Am J Roentgenol* 2003; 180(2): 425–428.
3. Blakeborough A, McWilliams RG, Raja U et al. Pseudolipoma of inverted Meckel's diverticulum: clinical, radiological and pathological correlation. *Eur Radiol* 1997; 7(6): 900–904.
4. Botha FJH, Zuckerman M, Grobler SP. Meckel's diverticulum with heterotopic gastric mucosal polyps. In: Mul-

der CJJ (ed). *Atlas of Double Balloon Endoscopy*. Munich: Medconnect 2007, 38–39.

5. Chen CM, Chao CC, Chiu HH. Meckel's diverticulum with recurrent bleeding diagnosed by double-balloon enteroscopy. *Clin Gastroenterol Hepatol* 2007; 5(10): e40–e41.
6. Chen YM, Teague RS, Wolfman NT et al. Inverted Meckel's diverticulum. *Comput Med Imaging Graph* 1989; 13(6): 477–479.
7. Cullen JJ, Kelly KA, Moir CR et al. Surgical management of Meckel's diverticulum. An epidemiologic, population-based study. *Ann Surg* 1994; 220(4): 564–568.
8. Doležal J, Vižďa J, Bureš J. Our ten-year clinical experience with Meckel's diverticulum scintigraphy. *Folia Gastroenterol Hepatol* 2005; 3(2): 52–55.
9. Drobčů J. Leiomyosarcoma of Meckel's diverticulum – a rare cause of acute hemorrhage in the lower part of the digestive system. *Rozhl Chir* 1999; 78(8): 375–377.
10. Dujardin M, de Beeck BO, Osteaux M. Inverted Meckel's diverticulum as a leading point for ileoileal intussusception in an adult: case report. *Abdomin Imaging* 2002; 27(5): 563–565.
11. Dumper J, Mackenzie S, Mitchell P et al. Complications of Meckel's diverticula in adults. *Can J Surg* 2006; 49(5): 353–357.
12. El-Dhuwaib Y, O'Shea S, Ammori BJ. Laparoscopic reduction of an ileoileal intussusception and resection of an inverted Meckel's diverticulum in an adult. *Surg Endosc* 2003; 17(7): 1157.
13. Elsayes KM, Menias CO, Harvin HJ et al. Imaging manifestation of Meckel's diverticulum. *AJR Am J Roentgenol* 2007; 189(1): 81–88.
14. Fetterman LE. Meckel's diverticulum radiographically appearing as a polyp (inverted). *Br J Radiol* 1968; 41(492): 940–941.
15. Gasbarrini A, Di Caro S, Mutignani M et al. Double-balloon enteroscopy for diagnosis of a Meckel's diverticu-

lum in a patient with GI bleeding of obscure origin. *Gastrointest Endosc* 2005; 61(6): 779–781.

16. Ge ZZ, Chen HY, Gao YJ et al. Clinical application of wireless capsule endoscopy in pediatric patients for suspected small bowel diseases. *Eur J Pediatr* 2007; 166(8): 825–829.
17. Hennenberg Holmboe C, Thorlacius-Ussing O, Teglbjaerg PS et al. Inverted Meckel's diverticulum masquerading Crohn disease in the small intestine. *Scand J Gastroenterol* 2003; 38(2): 225–227.
18. Horn F, Trnka J, Šimičková M et al. Symptomatic Meckel's diverticulum in children. *Rozhl Chir* 2007; 86(9): 480–482.
19. James GK, Berean KW, Nagy AG et al. Inverted Meckel's diverticulum: an entity simulating an ileal polyp. *Am J Gastroenterol* 1998; 93(9): 1554–1555.
20. Karadeniz Cakmak G, Emre AU, Tascilar O et al. Lipoma within inverted Meckel's diverticulum as a cause of recurrent partial intestinal obstruction and hemorrhage: a case report and review of literature. *World J Gastroenterol* 2007; 13(7): 1141–1143.
21. Kazemi K, Jalaeian H, Fattahi MR et al. Ruptured Meckel's mesodiverticulum and Meckel's diverticulum following blunt abdominal trauma. *Med Princ Pract* 2008; 17(2): 161–163.
22. Keljo DJ, Squires RH. Anatomy and anomalies of the small and large intestines. In: M Feldman, BF Scharschmidt, MH Sleisenger (eds). *Sleisenger & Fordtran's Gastrointestinal and Liver Disease*. 6th ed. Philadelphia: WB Saunders 1998, 1419–1436.
23. Kopáčová M, Bureš J, Vykouřil J et al. Intraoperative enteroscopy. Ten years' experience at a single tertiary centre. *Surg Endosc* 2007; 21(7): 1111–1116.
24. Krška Z. Meckel's diverticulum. *Čas Lék čes* 2006; 145(6): 427–429.
25. Levy AD, Hobbs CM. Meckel diverticulum: radiologic features with pathologic correlation. *Radiographics* 2004; 24(2): 565–587.

26. Moon JH, Park CH, Kim JH et al. Meckel's diverticulum bleeding detected by capsule endoscopy. *Gastrointest Endosc* 2006; 63(4): 702.
27. Moy L, Levine J. Wireless capsule endoscopy in the pediatric age group: experience and complications. *J Pediatr Gastroenterol Nutr* 2007; 44(4): 516–520.
28. Nakashima Y, Nakamura I, Miyatani H et al. Double-balloon enteroscopy for diagnosis of Meckel's diverticulum in a patient with gastrointestinal bleeding. *Endoscopy* 2007; 39 (Suppl 1): E140–E141.
29. Pantongrag-Brown L, Levine MS, Elsayed AM et al. Inverted Meckel diverticulum: clinical, radiologic, and pathologic findings. *Radiology* 1996; 199(3): 693–696.
30. Park JJ, Wolff BG, Tollefson MK et al. Meckel diverticulum: the Mayo Clinic experience with 1476 patients (1950–2002). *Ann Surg* 2005; 241(3): 529–533.
31. Ramsook C, Endom EE. Approach to lower gastrointestinal bleeding in children. *UpToDate* [online]. 2008, vol 16.1. Dostupné z: <http://www.uptodate.com/patients/content/topic.do?topicKey=~bJDbzKC8n2B/3J&selectedTitle=1~126&source=search_result>.
32. Shelton JH, Newsome TW, Ford KL et al. Inverted Meckel's diverticulum presenting as iron deficiency anemia. *Endoscopy* 2006; 38(Suppl 2): E93–E94.
33. Shindoh N, Kurosaki A, Ozaki Y et al. Characteristic angiographic appearance of inverted Meckel's diverticulum. *AJR Am J Roentgenol* 1997; 169(6): 1569–1571.
34. Simms M, Malatjalian DA, Fried L et al. Inverted Meckel's diverticulum simulating a pendulated small bowel polyp. *Abdom Imaging* 1995; 20(3): 236–237.
35. Soltero MJ, Bill AH. The natural history of Meckel's Diverticulum and its relation to incidental removal. A study of 202 cases of diseased Meckel's Diverticulum found in King County, Washington, over a fifteen year period. *Am J Surg* 1976; 132(2): 168–173.
36. Steinwald PM, Trachiotis GD, Tannenbaum IR. Insusception in an adult secondary to an inverted Meckel's diverticulum. *Am Surg* 1996; 62(11): 889–894.
37. Tabbers MM, Bruin KF, Taminiau JA et al. An unexpected finding in a child with rectal blood loss using video capsule endoscopy. *Eur J Pediatr* 2006; 165(4): 270–272.
38. Yahchouchy EK, Marano AF, Etienne JC et al. Meckel's diverticulum. *J Am Coll Surg* 2001; 192(5): 658–662.
39. You JS, Chung SP, Pak YS et al. A case of strangulated small bowel obstruction caused by Meckel's diverticulum in an adult. *J Emerg Med* 2007; 33(2): 133–135.
40. Zacharakis E, Papadopoulos V, Athanasiou T et al. An unusual presentation of Meckel diverticulum as strangulated femoral hernia. *South Med J* 2008; 101(1): 96–98.

Correspondence to/

Adresa pro korespondenci:

Jolana Bártová, MD

2nd Department of Medicine

Charles University Teaching Hospital

Sokolská 581

500 05 Hradec Králové

Czech Republic

e-mail: bartovaj@seznam.cz